

## Topical Medication Insect Bite Protection: Iraq/Afghanistan Cutaneous Leishmaniasis

January 17, 2005

There have been a significant number of cases of leishmaniasis (protozoan infection) of the skin in individuals travelling in Iraq and Afghanistan. At IMC we have just treated 8 individuals working in Iraq for multiple, chronic, nonhealing sores due to Leishmania. The parasite is acquired through sandfly bites. Most occur on the limbs, but can occur on any exposed skin. The problem can evolve to serious disease involving visceral organs – liver, spleen, bone marrow, etc.

Even when not invasive, the parasitic organism can cause disfiguring, painful, nonhealing soft tissue ulcers virtually anywhere. These sores are very prone to secondary bacterial infection (streptococcal, staphylococcal) which can have a serious outcome in medically remote areas.

**NOTE:** See the pictures below for a visual reference of typical lesions.

### RECOMMENDATIONS

#### 1) Prevention: bites

- Long-sleeved clothing/minimal skin exposure
- Mosquito nets
- **Military Insect Protection Protocol (Iraq, Afghanistan)**
  1. Skin: 3M – Ultrathon (30-33% DEET) – duration about 12 hours
  2. Clothing: Permethrin Spray – for added protection from flies
  3. Skin/Clothing: Broad Spectrum Spray (17% DEET + R326) – specific chemical combo for flies especially advised when sandflies noticeably present (“swarming”), in addition to the other measures.

#### 2) Treatment: Non-Healing Sores

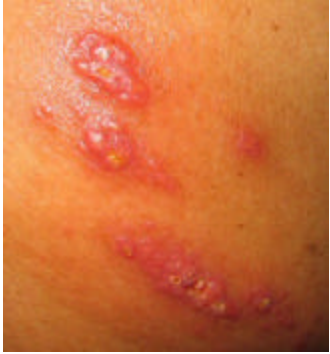- Keep clean (soap and H<sub>2</sub>O), dry, and covered.
- Medical evaluation ASAP
  - Biopsy for diagnosis
- Treatment: depends on the severity and extent of disease, and somewhat on the subspecies of Leishmania.

**Note:** Medications for systemic/visceral leishmaniasis are serious, potentially toxic, and not readily available (require application procedures to government agencies and/or pharmaceutical manufacturers for access to some specific treatment agents). This aspect underlines the importance of sandfly bite prevention.

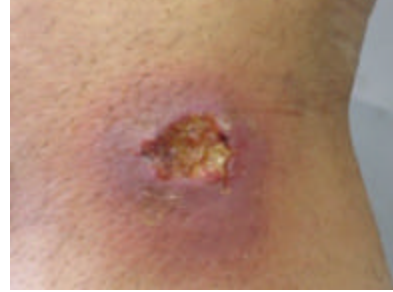
Edward R. Rensimer, MD, FACP  
Director, IMC

**Topical Medication Insect Bite Protection: Iraq/Afghanistan**  
**Cutaneous Leishmaniasis**  
**January 17, 2005**

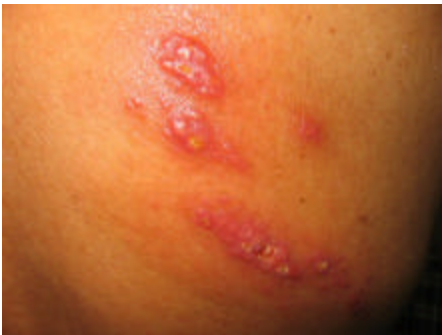**Cutaneous Leishmaniasis Lesions**



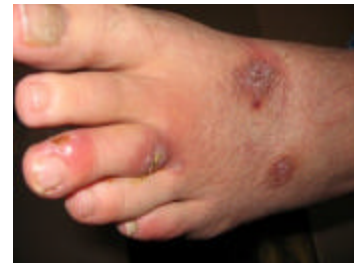*Lesions on back*



*Lesion on leg*



*Lesions on back*



*Lesions on foot*